


PATIENT PRESENTING CLINICAL SIGNS

Black Sabbath Krapf

History: Pancreatitis, diarrhea.

SPECIES

Physical Examination: N/A.

Feline

Urinalysis: N/A.

BREED

CBC: Mild anemia.

Maine Coon

Serum Biochemistry: Hyperglobulinemia.

Radiographic Findings: N/A.

SEX
ULTRASONOGRAPHIC EXAMINATION OF THE ABDOMEN

MN

Urinary System
AGE

Full urinary bladder with a normal thickness appearance of the wall. Normal anechoic urine with no sediment or uroliths evident.

11 years

WEIGHT

Normal trigone, proximal urethra (0.2 cm), and iliac blood vessels.

20 #

Normal iliac lymph nodes. Ureters not visualized.

INTERPRETED BY

Bilateral renomegaly (both 4.6 cm) with normal echogenic appearance, cortico-medullary differentiation, pelvis, and capsule.

 Remo Lobetti, BVSc,
MMedVet (Med), PhD,
Dipl. ECVIM

Reproductive System

N/A.

IMAGING PERFORMED BY
Adrenal Glands

Sonya Myers, DVM

Normal shape, echogenic appearance, size, and position. Left 0.44 cm, right 0.46 cm. Bilateral parenchymal mineralization.

HOSPITAL NAME
Spleen

 My Pets Wellness Port
Orange

Enlarged (1.5 cm) with a mottled echogenic appearance. Smooth homogenous parenchyma, regular capsule, and normal vasculature. Focal hyperechoic parenchymal nodule (1.2 cm) in the body of the spleen with resultant bulging of the over lying capsule.

REFERRING VET
Liver

Dr Tiffany

Enlarged with rounded edges, diffuse hypoechogenic appearance, and prominent portal markings. No nodules or masses evident. Full gall bladder containing normal anechoic bile. Thickened and hyperechogenic appearance of the gall bladder wall. Normal bile duct (0.2 cm).

INVOICE

303119

Gastrointestinal
DATE

Normal appearance of the stomach, duodenum, small intestine, ileo-cecal junction, and colon with no loss of layering, normal wall thickness (duodenum 0.25 cm, jejunum 0.29 cm) and peristaltic activity, and no distension of the lumen.

7/12/22


PATIENT *Pancreas*

Black Sabbath Krapf

Enlarged and irregular (left 0.5 cm, right 1.5 cm) with a hypoechogenic appearance of especially the right lobe. Multiple parenchymal cystic/anechoic nodules (up to 1.6 x 2.1 cm in size). Hyperechogenic appearance of the mesentery and fat surrounding the pancreas.

SPECIES

Feline

Free Abdomen
BREED

Maine Coon

Normal mesenteric lymph nodes (0.5 cm).
No ascites.

ULTRASONOGRAPHIC FINDINGS
SEX

Primary Findings:

MN

- Splenic pathology.
- Nodular pancreatitis.
- Hepatopathy.
- Renomegaly.

AGE

11 years

Secondary Findings:

WEIGHT

20 #

- Previous cholecystitis.
- Adrenal mineralization.

INTERPRETED BY

Remo Lobetti, BVSc,
MMedVet (Med), PhD,
Dipl. ECVIM

INTERPRETATION OF THE FINDINGS & FURTHER RECOMMENDATIONS

Etiologies for splenic pathology would be reactive hyperplasia, infiltrative neoplasia, splenitis, and granulomatous disease.

IMAGING PERFORMED BY

Sonya Myers, DVM

Etiologies for the pancreas would be chronic-active pancreatitis, pancreatic cysts, granulomatous disease, and neoplasia.

HOSPITAL NAME

My Pets Wellness Port
Orange

Etiologies for the hepatopathy would be reactive, hyperplasia, cholangio-hepatitis complex, granulomatous disease, and infiltrative neoplasia.

Further assessment would be fPL/PSL assay and FNA cytology of the spleen, liver, and pancreas.

REFERRING VET

Dr Tiffany

Specific therapy would be dependent on an etiological diagnosis.

INVOICE

303119

DATE

7/12/22



PATIENT

Black Sabbath Krapf

SPECIES

Feline

BREED

Maine Coon

SEX

MN

AGE

11 years

WEIGHT

20 #

INTERPRETED BY

Remo Lobetti, BVSc,
 MMedVet (Med), PhD,
 Dipl. ECVIM

IMAGING PERFORMED BY

Sonya Myers, DVM

HOSPITAL NAME

My Pets Wellness Port
 Orange

REFERRING VET

Dr Tiffany

INVOICE

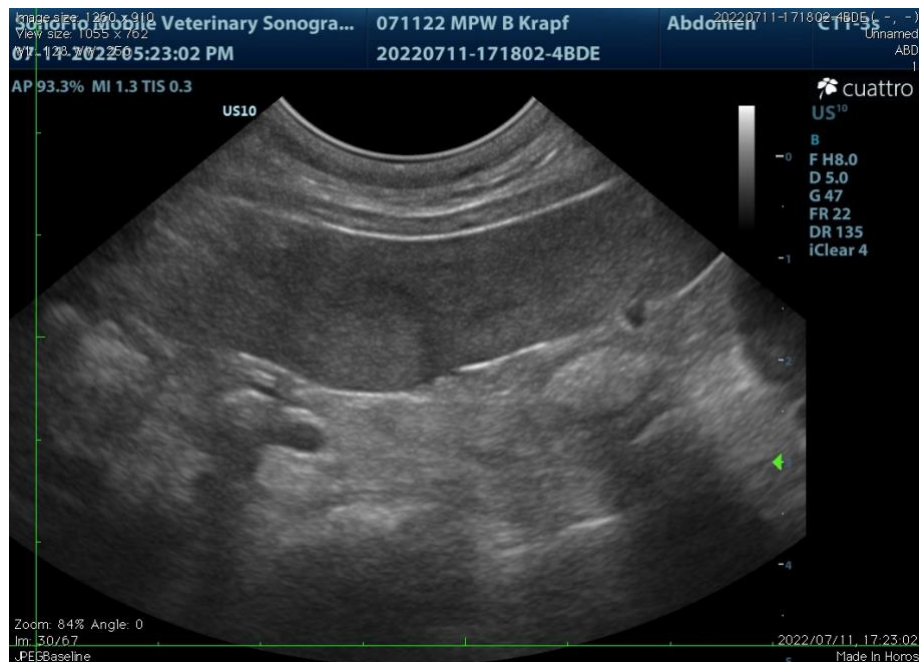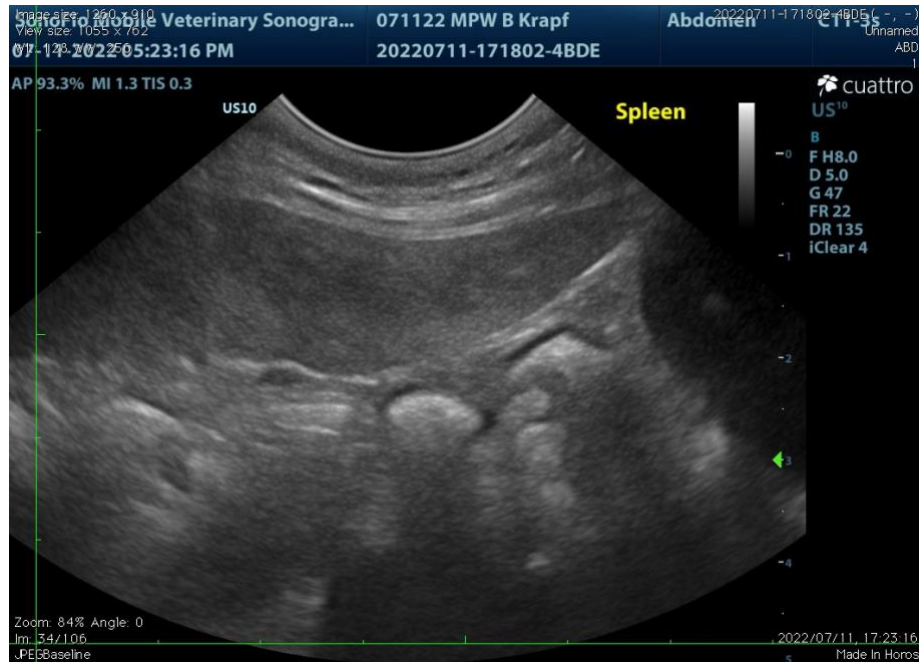303119

DATE

7/12/22

IMAGES

Spleen





PATIENT Pancreas

Black Sabbath Krapf

SPECIES

Feline

BREED

Maine Coon

SEX

MN

AGE

11 years

WEIGHT

20 #

INTERPRETED BY

Remo Lobetti, BVSc,
 MMedVet (Med), PhD,
 Dipl. ECVIM

IMAGING PERFORMED BY

Sonya Myers, DVM

HOSPITAL NAME

My Pets Wellness Port
 Orange

REFERRING VET

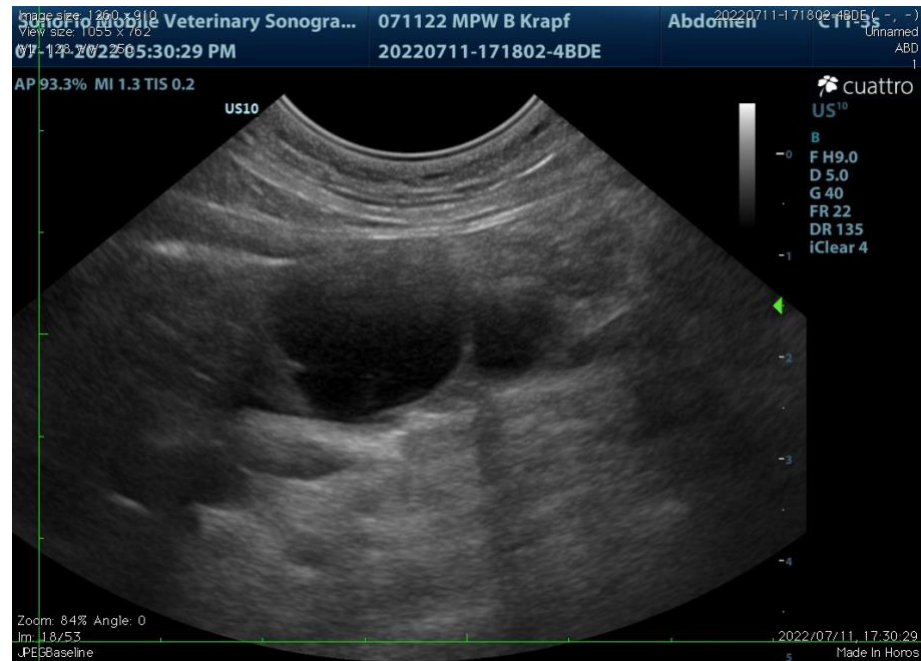
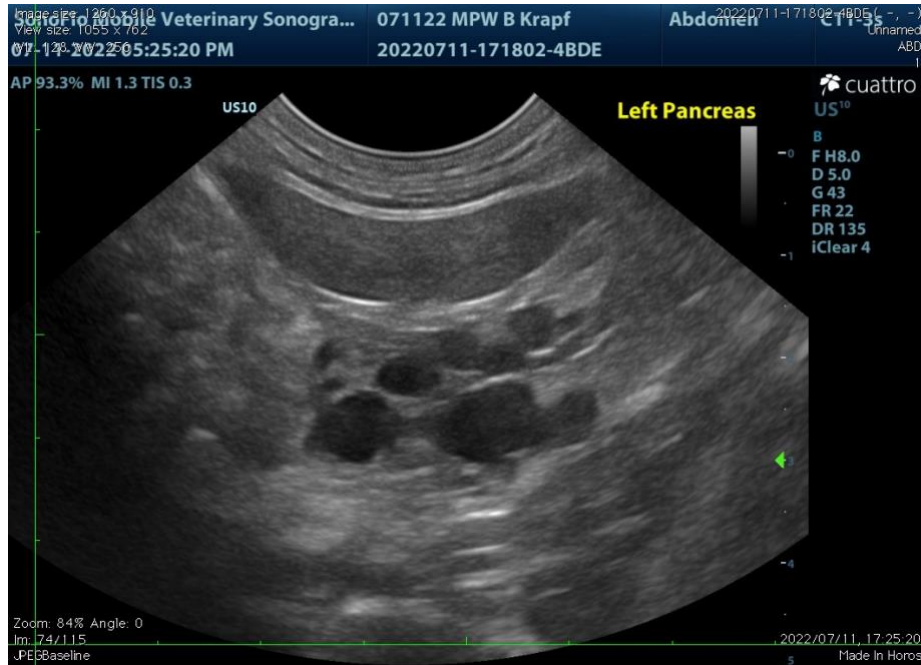Dr Tiffany

INVOICE

303119

DATE

7/12/22





PATIENT

Liver/gall bladder

Black Sabbath Krapf

SPECIES

Feline

BREED

Maine Coon

SEX

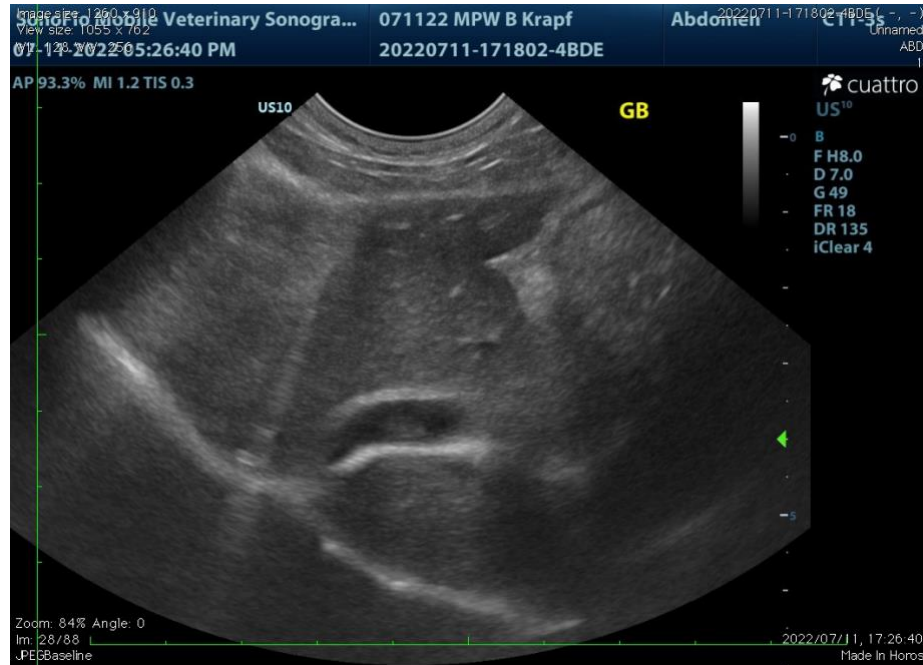MN

AGE

11 years

WEIGHT

20 #



INTERPRETED BY

Remo Lobetti, BVSc,
 MMedVet (Med), PhD,
 Dipl. ECVIM

The information and recommendations provided are based on the images presented by the referring veterinarian. No evaluation can be communicated regarding pathology that was not visible in the image/video clips provided.

IMAGING PERFORMED BY

Sonya Myers, DVM

Thank you for this referral. If the clinical or image interpretation does not parallel your findings or if I can be of any further assistance, please contact me.

HOSPITAL NAME

My Pets Wellness Port
 Orange

Remo Lobetti, BVSc, MMedVet (Med), PhD, Dipl. ECVIM (Internal Medicine)
rlobetti@mweb.co.za

REFERRING VET

Dr Tiffany

INVOICE

303119

DATE

7/12/22